

Herald of Science of S.Seifullin Kazakh Agrotechnical Research University: Veterinary Sciences.  
– Astana: S. Seifullin Kazakh Agrotechnical Research University, 2024. – № 2 (006). – P. 54-61.  
- ISSN 2958-5430, ISSN 2958-5449

doi.org/ 10.51452/kazatuvc.2024.2(006).1692

UDC 619:591.8:616-022:636.4(574.2)

### Histological studies of muscle tissue in swine sarcocystosis in the northern Kazakhstan

Kulyay U. Suleimanova<sup>1</sup> , Zhanaidar Zh. Bermukhametov<sup>2</sup> ,  
Oxana V. Tomaruk<sup>2</sup> , Raushan M. Rychshanova<sup>2</sup> 

<sup>1</sup>Kostanai Social-Technical University named after Academician Zулharnai Aldamjar,

<sup>2</sup>Akhmet Baitursynuly Kostanay Regional University, Kostanay, Kazakhstan

**Corresponding author:** Raushan M. Rychchanova: raushan5888@mail.ru

**Co-authors:** (1: KS) s.k.u.777@mail.ru; (2: ZhB) djon-31.01@mail.ru;

(3: OT) tomaruk.o@mail.ru

**Received:** 17-04-2023 **Accepted:** 26-06-2024 **Published online:** 28-06-2024

#### Abstract

**Background and Aim.** At present there is no information about the prevalence of sarcocystosis among pigs in Kazakhstan, so we aimed to study pork meat for the presence of sarcocysts in the muscles of pigs in the Kostanay region.

**Materials and Methods.** Pieces of heart muscle, neck, oesophagus, and diaphragm legs taken from pig carcasses served as material for the study. Sarcocysts presence in muscle slices was determined by viewing the samples stained with methylene blue under a microscope. Morphological analysis of muscle tissues included histological and histochemical methods.

**Results.** Muscle samples from 71 pig carcasses were examined. The intensity of sarcocystosis in pigs was 42.2%, and the intensity of invasion was 8.43 cysts. The highest infection with sarcocysts was found in sows 3-5 years old (29.6%). The predominant sarcocysts localisation was found: in the heart - 23.9%, oesophagus - 12.7%, and the diaphragm legs - 5.6%. Cervical muscles from the same animals were free of sarcocysts. *Sarcocystis suicanis* species was detected. Pathological changes in muscle fibres were detected in the examined muscle slices. Swellings and inflammatory processes of focal or diffuse character, as well as serous and less often purulent reactive myositis with infiltration and admixture of eosinophils or lymphocytes were noted. Examination of slices revealed an immunological reaction leading to disruption of the heart histological structure, the oesophagus fibres and the diaphragm legs.

**Conclusion.** Such animal muscles studies for sarcocystosis have not been conducted in the Kostanay region. The prevalence of infection from the number of the studied livestock were determined. According to studies in animals, the infection prevalence increases with age, which is associated with increased contact of pigs with primary hosts. According to the histological studies results, we have established inflammatory processes and muscle lesions caused by exposure to the product of parasite vital activity.

**Key words:** histology; microscopy; northern region of Kazakhstan; pig; sarcocystosis.

#### Introduction

Currently, more than two hundred species of *Sarcocystis* known as the most common parasites of domestic animals. According to researchers from different countries of the world, the extensiveness of *Sarcocystis* infection of pigs ranges from 3 to 36% worldwide; in particular, *S. suis* causes the disease in Germany, Austria, Japan, Malaysia, Argentina [1-3].

In Kazakhstan, information about animal sarcocystosis dates back to the 70-80s of the last century. It was only in 2008 that new information on sheep sarcocystosis was registered in Western Kazakhstan. To date, studies on pigs in the Kostanay region have not been conducted, and there is no information on the prevalence of this invasion. The lifetime diagnosis of sarcocystosis is very difficult, and postmortem diagnosis does not always allow the establishment of the causative agent, only with additional studies

[4-6]. Therefore, the purpose of our study was to identify *Sarcosystis spp.* in the muscles of pigs kept in LLP "Barvinovskoye", Sarykol district, Kostanay region, by microscopy and histological studies.

### Materials and methods

The material for the study were pieces of the heart muscle, neck, oesophagus, and legs of diaphragm weighting no more than 50 grams, taken from pig carcasses at the slaughterhouses of Kostanay in the period from August to October 2023. Visually examined 71 carcasses and selected 284 samples of muscle tissue. Further studies were conducted at the Research Institute of Applied Biotechnology, A. Baitursynuly Kostanay Regional University, and laboratory of patholoanatomical bureau.

From the selected pieces of muscle tissue, thin slices of no more than 5x5x2 mm were cut with curved eye scissors and prepared for examination by compressor microscopy. Next, the muscle pieces were spread on synthetic mesh and soaked in 0.2% aqueous solution of methylene blue for 20-30 minutes. After staining, the muscle pieces, along with the synthetic mesh, were placed on filter paper for drainage and removal of excess dye. The samples were kept on the filter paper for only a few seconds. The stained muscle pieces were immersed in 1.5% acetic acid solution for 15-20 minutes to clarify the samples. Gentle stirring was carried out to avoid sticking the samples. The samples were again placed on filter paper for drainage and then transferred to a glass compressor consisting of two glass plates tightened with screws and viewed under a microscope [7].

During microscopic examination, the number of sarcocysts in each slice was counted, and the intensity of invasion was determined by counting sarcocysts in 28 slices of muscle tissue; further, the invasion was conditionally classified as weak (up to 50), medium (above 50-200) and strong (above 200 sarcocysts). A total of 284 slices of muscle tissue from pigs belonging to "Barvinovsko-ye" LLP, Sarykol district, Kostanay region, were subjected to the study.

Morphological analysis of biopsy material included histological and histochemical methods of research; for this purpose, muscle tissue samples were sent to the laboratory of the regional pathological anatomical bureau of Kostanay. The muscular tissue samples were taken by biopsy in 1×1 cm, after which the material was fixed in 10% formalin solution, and then poured into paraffin according to the standard technique. Serial microtome sections 4-6 µm thick were deparaffinized in warm water according to the standardized scheme and stained with hematoxylin and eosin. Histologic evaluation of the severity of morphologic changes was carried out by semi-quantitative method using scores, where 1 "+" - weakly expressed, 2 "+" - moderately expressed, 3 "+" - strongly expressed, 4 "+" - very strongly expressed.

### Results

Muscles from 71 pig carcasses (sows 3-5 years old, young pigs 6-12 months old) were examined for the presence of sarcocysts. During visual inspection of pig carcasses, no pathological changes or macrocysts were found. Samples of muscle tissue infected with sarcocystis were sent to Kostanay regional patholo-anatomical bureau for histological examination. The biopsy specimen was taken 1×1 cm, after which the material was fixed in 10% formalin solution and then embedded in paraffin according to the standard technique. Serial microtome sections 4-6 µm thick were deparaffinized in warm water according to the standardized scheme and stained with hematoxylin and eosin.

Histologic studies revealed sarcocysts in all muscle tissue samples (Table 1).

Table 1 – Infection of pig muscle with sarcocysts

| Muscle tissue samples | Number of samples |          |
|-----------------------|-------------------|----------|
|                       | examined          | infected |
| Cardiac               | 71                | 17       |
| Oesophagus            | 71                | 9        |
| Cervical              | 71                | 0        |
| Diaphragm             | 71                | 4        |

The intensity of the invasion amounted to 8.43 cysts. The highest number of sarcocysts was found in cardiac muscle, slightly less in the oesophagus and diaphragm legs. Of the muscle samples examined, 17 cardiac muscle samples (23.9%) were the most infected, 9 oesophageal samples (12.7%) and 4 diaphragm leg samples (5.6%) were less infected. Cervical muscles appeared free of sarcocyst infection. The age-specific sarcocyst infection of pigs is presented in Table 2.

Table 2 – Infection of pigs by age

| Animal groups | Range of age | Number of samples |          | Percentage of infection, % |
|---------------|--------------|-------------------|----------|----------------------------|
|               |              | examined          | infected |                            |
| Sows          | 3-5 years    | 47                | 21       | 29.6                       |
| Piglets       | 6-12 months  | 24                | 9        | 12.6                       |
| Total         |              | 71                | 30       | 42.2                       |

Percentage of infection amounted to 42.2% (Table 2). The highest infection was found in sows 3-5 years old, while the young animals were less infected.

When comparing the size of the detected cysts, it was found that the largest cysts were found in the diaphragm and the smaller ones in the heart (Table 3).

Sarcocysts in cardiac muscle were oval-shaped with rounded ends, in the oesophagus oblong, in diaphragm legs elongated with pointed ends, sometimes spindle-shaped. At morphometry, the size of cysts varied from small to large; cysts in cardiac muscle averaged  $0.32\pm 0.67\times 0.5\pm 0.43$ , oesophagus  $2.11\pm 3.12\times 1.01\pm 1.13$ , diaphragm legs  $13.33\pm 1.56\times 12.28\pm 1.65$   $\mu\text{m}$ . According to morphometric features (wall thickness, presence of septa), the detected cysts corresponded to the description of *Sarcocystis suicanis* species [8, 9].

Table 3 – Dimensions ( $\mu\text{m}$ ) of detected pig sarcocysts

| Muscle tissue samples | length $\times$ width (max - min) | average $M\pm m$                  |
|-----------------------|-----------------------------------|-----------------------------------|
| cardiac               | 0.14–0.35 $\times$ 0.2–0.37       | $0.24\pm 0.67\times 0.28\pm 0.43$ |
| esophagus             | 3.24–3.35 $\times$ 0.7–1.17       | $3.29\pm 3.12\times 0.93\pm 1.13$ |
| cervical              | -                                 | -                                 |
| diaphragm             | 8.58-10.55 x 13.30-16.72          | $9.56\pm 1.56\times 9.01\pm 1.65$ |

Samples of muscles infected with sarcocysts were sent for histological studies, where pathological changes of muscle fibers were detected in the examined slices. In the sample (Fig. 1-3) from the heart, oesophagus and diaphragm stained with hematoxylin and eosin, longitudinal sections and partially transverse sections of muscle fibers were determined in most fields of view.

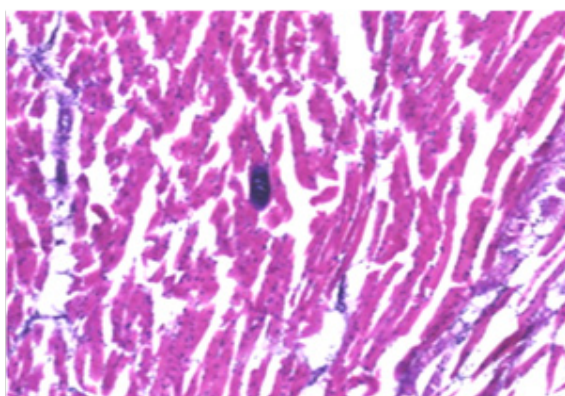


Figure – 1 *Sarcocystis* in cardiac muscle, second generation meronch filled with endozoites, hematoxylin and eosin staining  $\times 200$

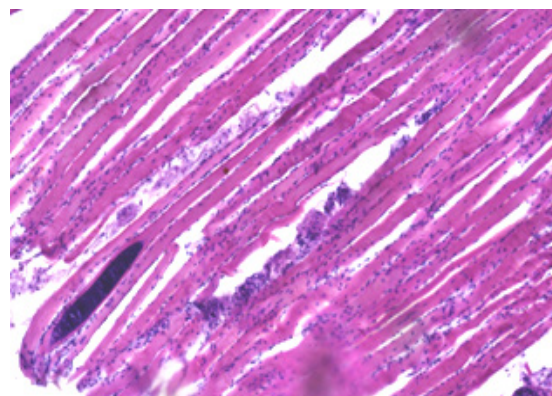


Figure – 2 *Sarcocystis* in the esophagus, hematoxylin and eosin staining  $\times 200$

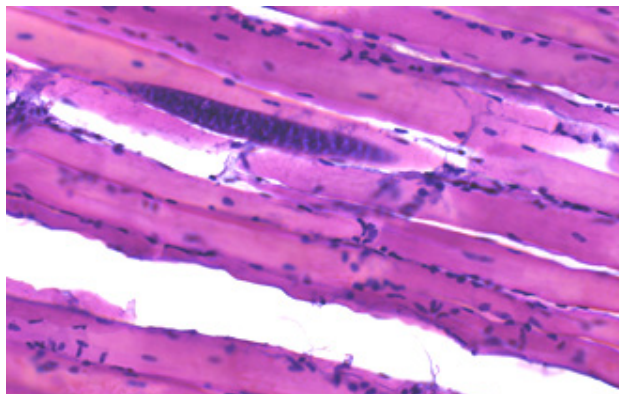


Figure 3 – *Sarcocystis* in the diaphragm hematoxylin and eosin staining  $\times 200$

The histologic section (Fig. 1) showed an area of intensive lesion with sarcocysts (5-6 larval capsules). Transverse striation was absent in the affected muscle fibers; sarcoplasm had a connective tissue capsule of oval and round shape around the juvenile stage of cyst development. On the periphery of the cyst capsule, there was nonspecific inflammation in the form of lymphohistiocytic infiltration with the admixture of lymphocytes. The degree of inflammation of muscle tissue at a distance from the lesion area is visualized as focal serous myositis.

In preparations from the oesophagus and diaphragm (Figs. 2, 3), sections of transverse striated muscle tissue were determined. Longitudinal slices of muscle fibers were visible in most fields of view. The muscle to adipose tissue ratio was 18:1 and 23:1. Epimysium was not detected. The perimysium of samples taken from the esophagus was of normal thickness and structure; in the diaphragm, it was thickened due to the proliferation of the connective-tissue component, which indicates fibrosis. The density of vessels was moderate, and single nerve trunks were determined. The density of endomysial slits was average, containing a moderate number of the capillary lumen and fibroblast nuclei. The sarcoplasm was slightly thickened, and muscle fiber nuclei were located parallel to the periphery of the longitudinal line of the muscle fiber. Transverse striation in unaffected muscle fibers was preserved, myoglobin saturation was sufficient, and muscle fibers were thinned. Five sarcocysts were found on the affected area of the histological section, where transverse striation in the affected muscle fibers was absent. The sarcoplasm had a connective tissue capsule that was oval and round in shape around the juvenile stage of cyst development. On examination of the periphery of the cyst capsule, nonspecific inflammation in the form of lymphohistiocytic infiltration with an admixture of lymphocytes was determined. The degree of inflammation of muscle tissue at a distance from the lesion area was visualized as focal serous myositis. A fragment of muscle fiber was red-brown in color, with fat and connective tissue layers, atrophic changes of parenchymatous cells, the proliferative reaction of lymphoid tissue were determined, which, apparently, were caused by intoxication of the organism with decay products of muscle fibers affected by sarcocysts and its viability. The inflammatory reaction was accompanied by microscopic lesions in the heart and diaphragm. The detection of cysts in the heart muscles indicates a defenseadaptive reaction of the organism of sick animals.



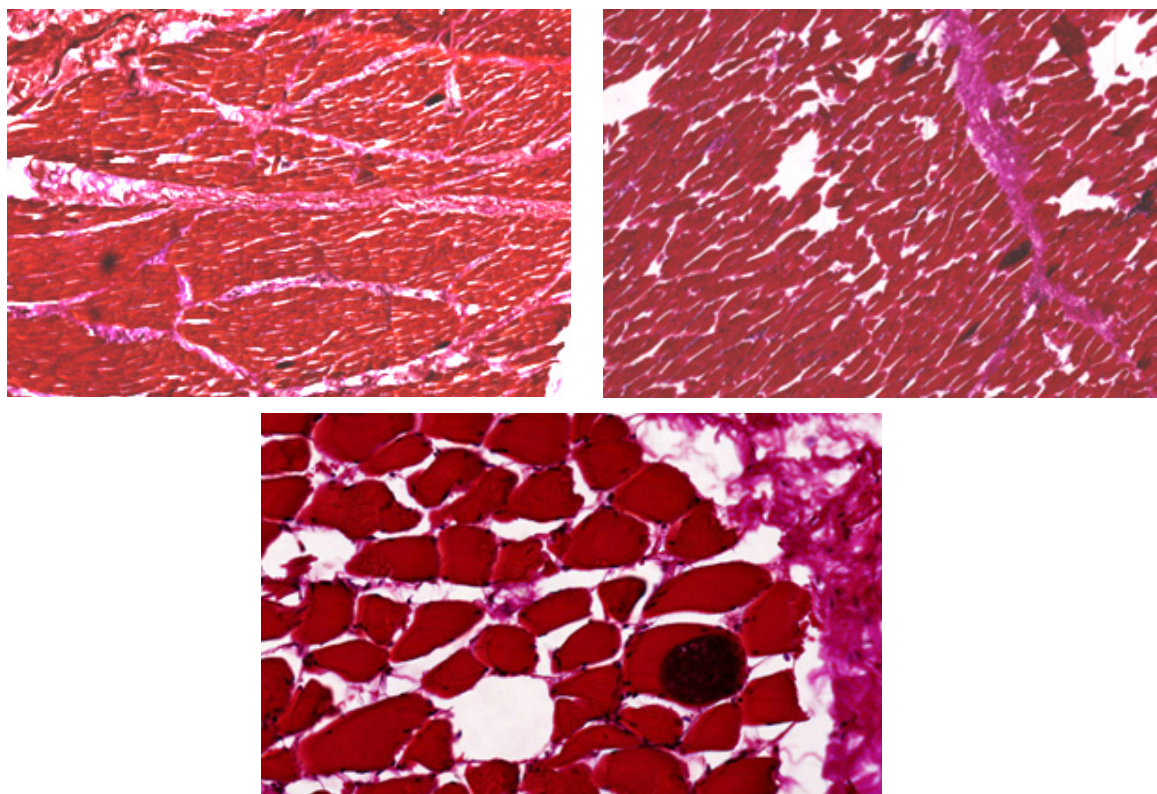


Figure 4-6 – *Sarcocysts* by Van Gieson staining, ×200

At additional histochemical staining by Van- Gieson (Fig.4 - 6), the fragments of muscle fibers were red-brown, with fat and connective tissue layers. Fibrous fibers were bright crimson, density and areas of occurrence were increased due to concentric structures on the periphery of neuro-vascular bundles and due to the thickening of perimysium fibers deeply embedded in endomysial spaces. The reaction of muscle fibers was greenish-brown, indicating an inflammatory process in the tissues.

### Discussion

The obtained data testify to pigs' average extensiveness and weak intensity of invasion. Analysis of histological sections of muscle tissue of the studied animals showed that the presence of cyst capsules with endozoites was noted in the sections. A small number of connective tissue fibers around the cysts with hardly visible capsules was revealed, due to which we assume *Sarcocystis suicanis* invasion.

According to Maslennikova O.V., *Sarcocystis miescheriana* (*S. suicanis*) in wild boars was registered in Belarus in the muscles of the diaphragm and heart with a relatively low intensity of invasion - 9.2%, and in Ukraine - 46.5% [10]. In pigs in the Omsk region, the extensiveness of sarcocystosis invasion is high and ranges from 26.3 to 75.0% [11]. There are no data on the prevalence of sarcocystosis in pigs in Kazakhstan in general and in the Kostanay region in particular.

It is known that domestic pigs and wild boars are intermediate hosts of several species of sarcocysts pathogens: *S.suicanis*, *S.suifelis*, *S.suihominis*. Their definitive hosts are dogs, cats and humans [12-14].

In histological studies, sarcocysts were identified in all muscle tissue samples. The total infection of muscle tissue samples was 42.2%. The highest infection was found in sows 3-5 years old (29,6%), and young animals were less infected at 12,6%. The predominant localization of sarcocysts in the heart, esophagus, diaphragm of pigs was determined: in the heart - 23,9%, oesophagus - 12,7%, and legs of the diaphragm - 5,6%. Cervical muscles from the same animals were free of sarcocysts. The size of sarcocysts in pigs corresponds to *S. suicanis* [13, 15, 16].

Muscle sections showed edema and inflammatory processes of focal serous or diffuse character, serous and less often purulent reactive myositis with infiltration and admixture of eosinophils or lymphocytes. Examination of slices revealed immune-allergic reaction leading to disruption of the histological structure of the heart, oesophageal fibers and legs of the diaphragm. Sarcocysts can be

detected only by microscopic examination due to their small size. According to Salimov V.A. and others [17], when muscle tissue is affected by sarcocysts, carcasses become more contaminated with microflora, meat matures poorly, taste and nutritional properties deteriorate, and shelf-life decreases.

### Conclusion

In this way, we have established for the first time the infection of pigs with sarcocystosis on the territory of the Kostanay region. The prevalence amounted to 42.2% of the number of the studied livestock. The intensity of invasion amounted to 8.43 cysts. During the examination of pig muscle samples, *S. suicanis* species was detected. In sows of 3-5 years of age, the infestation rate was 29.6%, while young animals were less infected and the infection rate was 12.6%. Localization of sarcocysts was observed mainly in the heart, oesophagus and diaphragm of pigs: 23.9% in the heart, 12.7% in the esophagus and 5.6% in the legs of the diaphragm. No sarcocysts were found in neck muscles. Histologic studies revealed inflammatory processes and muscle lesions in the form of focal serous myositis, most likely caused by exposure to the product of sarcocysts vital activity. To reduce the extensiveness and intensity of defining hosts defeat by sarcocystis invasion, we recommend not to allow feeding raw meat of pigs to dogs, cats and other carnivorous animals. Given the economic damage and epizootic and epidemic significance of the disease, it is necessary to ensure timely pre-ventive measures against the leading carriers of infection.

### Authors' Contributions

ZhB and OT: Conceptualized and designed the study, conducted a comprehensive literature search, analyzed the gathered data and drafted the manuscript. KS and RR: Conducted the final revision and proofreading of the manuscript. All authors have read, reviewed, and approved the final manuscript".

### Information on funding

This article was conducted with the support of the grant funding IRN AP14869992, entitled "Monitoring the spread of sarcocystosis in domestic animals in the context of food safety".

### Conflicts of Interest

Authors have no conflict of interest to declare.

### References

- 1 Климова, Е.С. Эпизоотология саркоцистоза домашних и диких жвачных животных [Текст] / Е.С. Климова, М.Э. Мкртчян // Теория и практика борьбы с паразитарными болезнями. - 2020. - № 21. - С.137-141.
- 2 Гадоев, А. Заражённость домашних животных саркоспоридиями в зависимости от пола [Текст] / А. Гадоев, М. Туркистанова, Г. Гадоева, Х. Комилова // Экономика и социум. - 2020. - № 12(79). - Р. 454-456.
- 3 Helman, E. Morphological and molecular characterization of *Sarcocystis* spp. in pigs (*Sus scrofa domestica*) from Argentina [Text] / E. Helman, A. Dellarupe, K.D. Steffen, M. Bernstein, G. Moré // *Parasitology International*. - 2024. - Vol. 100:102859. DOI: 10.1016/j.parint.2024.102859.
- 4 Яникина, М.А. Болезни свиней [Текст] / М.А. Яникина // Вестник науки. - 2021. - № 1(34). - С. 211-215.
- 5 Масленникова, О.В. Саркоцистоз кабанов и диких уток на севере Нечерноземья [Текст] / О.В. Масленникова // Теория и практика борьбы с паразитарными болезнями. - 2019. - № 20. - С.347-352. DOI: 10.31016/978-5-9902340-8-6.2019.20.347-352
- 6 Гламаздин, И. Г. Эффективность иммунодиагностических исследований при тканевых паразитозах свиней [Текст] / И. Г. Гламаздин, Н. Ю. Сысоева, Г. М. Крюковская, Е. В. Ли // *Health, Food & Biotechnology*. - 2019. Т 1. - № 4. DOI: 10.36107/hfb. 2019.i4.s274
- 7 Gazzonis, A. L. Prevalence and molecular characterisation of *Sarcocystis miescheriana* and *Sarcocystis suis hominis* in wild boars (*Sus scrofa*) in Italy [Text] / A. L. Gazzonis, B. Gjerde, L. Vil-la,

S. Minazzi, S. A. Zanzani, P. Riccaboni, G. Sironi, M. Manfredi / Parasitology research. - 2019. - Vol. 118(4). - P.1271-1287. DOI: 10.1007/s00436-019-06249-2

8 Prakas, P. Molecular identification of Sarcocystis species in sika deer (*Cervus nippon*) of free-ranging populations in Germany and Austria [Text] / P. Prakas, S. Rehbein, E. Rudaitytė-Lukošienė, D. Butkauskas // Veterinary Research Communications. - 2023. - Vol. 47(4). - P. 2165-2171. DOI: 10.1007/s11259-023-10079-0.

9 Околелов, В.И. Диагностика саркоцистоза животных в омском регионе [Текст] / В.И. Околелов, Т.Ю. Чеботарева, А.М. Иванюшина, А.О. Фомченко // Ветеринария. - 2019. - № 9. - С.23-25. DOI:10.30896/0042-4846.2019.22.9.23-26

10 Околелов, В.И. Саркоцистоз свиней в Омской области [Текст] / В.И. Околелов, Т. Ю. Чеботарева // Вестник ОмГАУ. - 2013. - № 4(12). - P.35-39.

11 Pacifico, L. Molecular differentiation of *Sarcocystis miescheriana* and *Sarcocystis suihominis* using a new multiplex PCR targeting the mtDNA *cox1* gene in wild boars in southern Italy [Text] / L. Pacifico, S. Rubiola, F. Buono, M. Sgadari, N. D'Alessio, S. Scarcelli, G. Sgroi, M. Bu-glione, F. Chiesa, B. Restucci, A. Fioretti, P. Prakas, V. Veneziano // Research in Veterinary Science. - 2023. - Vol. 164: 105039. DOI: 10.1016/j.rvsc.2023.105039.

12 Chauhan, R.P. Genetic characterization and phylogenetic analysis of *Sarcocystis suihominis* infecting domestic pigs (*Sus scrofa*) in India [Text] / R.P. Chauhan, A. Kumari, A.K. Nehra, H. Ram, R. Garg, P.S. Banerjee, M. Karikalan, A.K. Sharma // Parasitology research. - 2020. - Vol. 119(10). - P. 3347-3357. DOI: 10.1007/s00436-020-06857-3.

13 Гаджиева, Н.А. Саркоспоридии (Аpicomplexa: Sporozoa) свиней в хозяйствах Апшерона [Текст] / Н.А. Гаджиева // Вестник Дагестанского государственного университета. Серия 1: Естественные науки. - 2015. - № 6. - С.174-178.

14 Chauhan, R. P. Genetic characterization and phylogenetic analysis of *Sarcocystis suihominis* infecting domestic pigs (*Sus scrofa*) in India [Text] / R. P. Chauhan, A. Kumari, A. K. Nehra, H. Ram, R. Garg, P. S. Banerjee, M. Karikalan, A.K. Sharma, // Parasitology research. -2020. - Vol. 119(10). - P. 3347-3357. DOI: 10.1007/s00436-020-06857-3

15 Huang, Z. Morphological and molecular characterizations of *Sarcocystis miescheriana* and *Sarcocystis suihominis* in domestic pigs (*Sus scrofa*) in China [Text] / Z. Huang, Y. Ye, H. Zhang, S. Deng, J. Tao, J. Hu, Y. Yang / Parasitology research. - 2019. - Vol. 118(12). - P.3491-3496. DOI: 10.1007/s00436-019-06521-5

16 Стаффорд, В. В. *Sarcocystis* spp.: гистологическое исследование и морфометрия [Текст] / В. В. Стаффорд // Российский паразитологический журнал. - 2023. - № 17(4). - P. 453-458.

17 Салимов, В.А. Саркоцистоз крупного рогатого скота [Текст]: монография // В.А. Салимов, В.И. Абакумов, Р.Р. Гасанов, О.С. Салимова. -Самара: ФГБОУ ВПО Самарской ГСХА. 2013. - 192 с.

## References

1 Klimova, E.S., Mkrtychyan, M.E. (2020). Epizootologiya sarkocistoza domashnih i dikih zhvachgyh zhivotnyh [Epizootology of sarcocystosis of domestic and wild ruminants]. *Teoriya i praktika bor'by s parazitarnymi boleznyami [Theory and practice of fighting parasitic diseases]*, [In Russ], 21, 137-141.

2 Gadoev, A., Turkistanova, M., Gadoeva, G., Komilova, H. (2020). Zarazhyonnost' domashnih zhivotnyh sarkosporidiyami v zavisimosti ot pola [Infection of domestic animals with sarcosporidia depending on their sex]. *Ekonomika i socium [Economy and socium]*, [In Russ], 12 (79), 454-456.

3 Helman, E., Dellarupe, A., Steffen, K. D., Bernstein, M., Moré, G. (2024). Morphological and molecular characterization of *Sarcocystis* spp. in pigs (*Sus scrofa domestica*) from Argentina. *Parasitology international*, 100, 102859. DOI: 10.1016/j.parint.2024.102859

4 YAnikina, M.A. (2021). Bolezni svinej [Diseases of pigs]. *Vestnik nauki [Bulletin of Science]*, [In Russ], 1(34), 211-215.

5 Maslennikova, O.V. (2019). Sarkocistoz kabanov i dikih utok na severe Nechernozem'ya [Sarcocystosis of wild boars and wild ducks in the north of the Non-Black Earth Region]. *Teoriya*



*i praktika bor'by s parazitarnymi boleznyami [Theory and practice of fighting parasitic diseases]*, [In Russ], 20, 347-352.

6 Glamazdin, I.G., Sysoeva, N.YU., Kryukovskaya, G.M., Li, E.V. (2019). Effektivnost' immunodiagnosticheskikh issledovanij pri tkanevyh parazitozah svinej [Effectiveness of immunodiagnostic studies in tissue parasitosis of pigs]. *Health, Food & Biotechnology*, 1,4:11-18. DOI:10.36107/hfb.2019.i4.s274

7 Gazzonis, A. L., Gjerde, B., Villa, L., Minazzi, S., Zanzani, S. A., Riccaboni, P., Sironi, G., Manfredi, M. T. (2019). Prevalence and molecular characterisation of *Sarcocystis miescheriana* and *Sarcocystis suis hominis* in wild boars (*Sus scrofa*) in Italy. *Parasitology research*, 118(4), 1271–1287. DOI:10.1007/s00436-019-06249-2

8 Prakas, P., Rehbein, S., Rudaitytė-Lukošienė, E., Butkauskas, D. (2023). Molecular identification of *Sarcocystis* species in sika deer (*Cervus nippon*) of free-ranging populations in Germany and Austria. *Veterinary research communications*, 47(4), 2165-2171. DOI: T10.1007/s11259-023-10079-0

9 Okolelov, V.I., Chebotareva, T.YU., Ivanyushina, A.M., Fomchenko, A.O. (2019). Diagnostika sarkocistoza zhivotnyh v omskom regione [Diagnosis of animal sarcocystosis in the Omsk region]. *Veterinariya [Veterinary]*, [In Russ], 9, 23-25. DOI:10.30896/0042-4846.2019.22.9.23-26

10 Okolelov, V.I., Chebotareva, T.Ju. (2013). Sarkocistoz svinej v Omskoj oblasti [Sarcocystosis of pigs in the Omsk region]. *Vestnik Omskogo gosudarstvennogo agrarnogo universiteta [Bulletin of the Omsk State Agrarian University]*, [In Russ], 4(12), 35-39.

11 Pacifico, L., Rubiola, S., Buono, F., Sgadari, M., D'Alessio, N., Scarcelli, S., Sgroi, G., Buglione, M., Chiesa, F., Restucci, B., Fioretti, A., Prakas, P., Veneziano, V. (2023). Molecular differentiation of *Sarcocystis miescheriana* and *Sarcocystis suis hominis* using a new multiplex PCR targeting the mtDNA *cox1* gene in wild boars in southern Italy. *Research in veterinary science*, 164, 105039. DOI: 10.1016/j.rvsc.2023.105039

12 Chauhan, R. P., Kumari, A., Nehra, A. K., Ram, H., Garg, R., Banerjee, P. S., Karikalan, M., Sharma, A. K. (2020). Genetic characterization and phylogenetic analysis of *Sarcocystis suis hominis* infecting domestic pigs (*Sus scrofa*) in India. *Parasitology research*, 119(10), 3347-3357. DOI:10.1007/s00436-020-06857-3

13 Gadzhieva, N.A. (2015). Sarkosporidii (Apicomplexa: Sporozoa) svinej v hozyajstvakh Apsherona [Sarcosporidia (Apicomplexa: Sporozoa) of pigs in Apsheron farms]. *Vestnik Dagestanskogo gosudarstvennogo universiteta [Bulletin of Dagestan State University]*, [In Russ], 6, 174-178.

14 Chauhan, R. P., Kumari, A., Nehra, A. K., Ram, H., Garg, R., Banerjee, P. S., Karikalan, M., Sharma, A. K. (2020). Genetic characterization and phylogenetic analysis of *Sarcocystis suis hominis* infecting domestic pigs (*Sus scrofa*) in India. *Parasitology research*, 119(10), 3347-3357. DOI: 10.1007/s00436-020-06857-3

15 Huang, Z., Ye, Y., Zhang, H., Deng, S., Tao, J., Hu, J., Yang, Y. (2019). Morphological and molecular characterizations of *Sarcocystis miescheriana* and *Sarcocystis suis hominis* in domestic pigs (*Sus scrofa*) in China. *Parasitology research*, 118(12), 3491-3496. DOI: 10.1007/s00436-019-06521-5

16 Stafford, V.V. (2023). *Sarcocystis* spp.: gistologicheskoe issledovanie i morfometriya [Sarcocystis spp.: histological study and morphometry]. *Rossijskij parazitologicheskij zhurnal [Russian Parasitological Journal]*, [In Russ], 17(4), 453-458. DOI: 10.31016/1998-8435-2023-17-4-453-458

17 Salimov, V.A., Abakumov, V.I., Gasanov, R.R., Salimova, O.S. (2013). Sarkocistoz krupnogo rogatogo skota. Monografiya [Sarcocystosis of cattle. Monograph]. Samara: FGBOU VPO Samarskoj GSHA [Samara: FSBEI HE Samara SAA], 192.